

Topical Tretinoin in the Management of Thick-skinned Rhinoplasty Patients

Hamidreza Rastiboroujeni^{1#}, Mehdi Bakhshae^{2#}, Mohamad Reza Afzalzadeh^{2*},
Yalda Nahidi³

1. Department of Otolaryngology, School of Medicine, Aja University of Medical Sciences, Tehran, Iran.

2. Sinus and Surgical Endoscopic Research Center, Department of Otorhinolaryngology, School of Medicine, Mashhad University of Medical Sciences, Mashhad, Iran.

3. Cutaneous Leishmaniasis Research Center, Department of Dermatology, School of Medicine, Mashhad University of Medical Sciences, Mashhad, Iran.

Hamidreza Rastiboroujeni and Mehdi Bakhshae contributed equally to this work

ABSTRACT

Background: Despite the increasing popularity of cosmetic surgeries, some patients still experience skin problems, particularly those with thick nasal skin. Isotretinoin is a commonly used drug for severe acne, and its effects on rhinoplasty aesthetic results have recently been studied. This placebo-controlled clinical trial aimed to investigate the effects of topical tretinoin gel on the cosmetic outcomes of rhinoplasty in patients with thick nasal skin.

Methods: Forty-nine individuals were randomly allocated to either the treatment group or the control group in Mashhad, Iran from 2019 to 2021. The treatment group received topical tretinoin gel (0.05%) beginning on the 31st postoperative day and continued for six months, while the control group received a usual dermatological recommendation as a placebo. Patients were assessed during the first, third, and sixth months after the intervention, and their cosmetic results were evaluated by an expert surgeon and dermatologist.

Results: There were no significant differences in baseline features between the two groups. The median score given by the surgeon was not significantly different between the groups. However, the median score given by the dermatologist was significantly higher in the treatment group during the first, third, and sixth months ($P < 0.001$). Patient satisfaction scores were also significantly higher in the treatment group during the third and sixth months compared to the control group. ($P = 0.02$ and 0.01 , respectively).

Conclusion: Topical tretinoin gel could effectively reduce acne in patients with thick nasal skin after rhinoplasty and increase patient satisfaction in the early months following surgery. However, it did not significantly affect final cosmetic outcomes.

KEYWORDS

Tretinoin; Rhinoplasty; Plastic Surgery

Please cite this paper as:

Rastiboroujeni H., Bakhshae M., Afzalzadeh MR., Nahidi Y. Topical Tretinoin in the Management of Thick-skinned Rhinoplasty Patients. *World J Plast Surg.* 2024;13(1):50-56.

doi: 10.61186/wjps.13.1.50

*Corresponding Author:

Mohamad Reza Afzalzadeh, MD

Sinus and Surgical Endoscopic Research Center, Department of Otorhinolaryngology, School of Medicine, Mashhad University of Medical Sciences, Mashhad, Iran.

Email: afzalzadehmr@mums.ac.ir

Received: 12/2/2023

Accepted: 2/20/2024

INTRODUCTION

Facial plastic surgery, particularly rhinoplasty, has become increasingly popular worldwide. However, performing rhinoplasty on patients with thick nasal skin can be challenging due to the difficulty in creating contours and delicate tip definition during surgery¹. This is especially true for individuals of African and Middle Eastern descent, who often have

weak nasal cartilages and thick skin². While multiple grafts can help augment the bony cartilaginous framework, the results are often unsatisfactory for most patients, particularly adolescents who may be susceptible to acne on the face³.

Isotretinoin has been used extensively over the years to treat rhinophyma and acne. Some studies have explored the use of oral isotretinoin to enhance tip definition in individuals with thick skin⁴. Guyuron and Lee developed a systemic algorithm to manage rhinoplasty patients with thick nasal skin, highlighting the importance of managing the skin phase⁵. Topical Retin-A was suggested as an essential consideration for patients with sebaceous overactivity. However, oral isotretinoin can have significant systemic effects, leading researchers to explore the use of topical tretinoin, which has fewer side effects, in managing rhinoplasty in thick-skinned patients.

We aimed to assess the effects of topical tretinoin on rhinoplasty management in thick-skinned patients for the first time

METHODS

This prospective cohort study was conducted in Mashhad, Iran from 2019 to 2021. We enrolled individuals between the ages of 16 and 60 yr who were candidates for rhinoplasty. Patients with thick and oily nasal skin, as determined by a dermatologist, were eligible for inclusion. Exclusion criteria consisted of contraindications to tretinoin use, such as sensitive and dry skin, history of skin allergies, pregnancy or breastfeeding, revision rhinoplasty, and unwillingness to participate.

The study was performed in a blinded fashion, with the dermatologist, otolaryngologist, photographer, and surgeon unaware of which group (case or control) each patient belonged to. All surgeries were performed using an open method by the senior author.

Participants either were randomly assigned to the experimental or control group in a 1:1 ratio. One month after surgery, the experimental group received daily topical tretinoin gel for six months, while the control group received a placebo that resembled the tretinoin gel. The prescription schedule and method were identical for both groups. Postoperative photos were taken at one, three, and six months following the procedure, and a blinded

otolaryngologist compared the aesthetic outcomes using a five-point grading scale (excellent, good, fair, no change, and poor). Participants were asked to rate their aesthetic satisfaction at one, three, and six months post-treatment, using the same five-point scale. A dermatologist evaluated the nasal skin before surgery, as well as one, three, and six months after treatment, using a five-point scale to rate the skin appearance (seborrheic dermatitis, moderate acne, mild acne, almost clear, and normal skin).

All the included participants signed the written constant form. The Ethics Committee of Mashhad University of Medical Sciences approved this study with ethics code of IR.MUMS.MEDICAL.REC.1400.036.

RESULTS

Fifty patients had the inclusion criteria among 70 rhinoplasty patients, and twenty were removed from the study. Among forty-nine patients (with a 98% compliance rate) following surgery and at the 6-month follow-up, one participant was lost to follow-up (Fig. 1). However, no significant difference was found between experimental, and control groups (Table 1).

The surgeon's score, as depicted in Fig. 2 and Table 2, did not reveal any significant differences between the two study groups at any of the follow-up time points. However, both groups demonstrated an increasing trend of change over the course of the study.

In the first month, the dermatologist's score showed a significant difference between the study groups. (P Value < 0.001) Additionally, the tretinoin group had significantly higher scores than the control group in the third- and sixth-month follow-ups, as demonstrated by Table 3 and Fig. 3. Furthermore, both groups showed an increasing trend of change in the dermatologist's scores throughout the study.

Upon further analysis, patient satisfaction scores increased significantly in both groups during the study. Initially, there were no significant differences in the participants' scores between the experimental and control groups. Besides, there were no differences were observed at the first-month follow-up. Nevertheless, significant differences were observed in the third- and sixth-month follow-ups, as presented in Table 4 and Fig. 4.

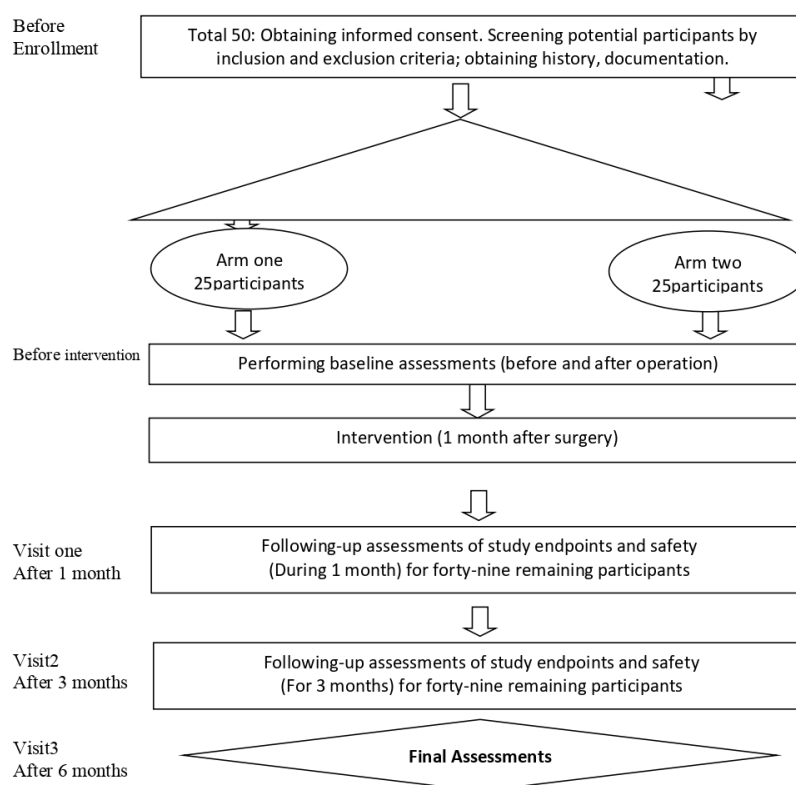


Figure 1: The patient’s enrolment in the study

Table 1: Clinical and demographic features of 49 Rhinoplasty candidate patients based on allocation to new treatment (isotretinoin) or placebo.

VAR	TRETINOIN N=24	CONTROL N=25	P VALUE
AGE(YEAR)	27.5(22.5-31.7)	25.0(24.0-30.0)	0.74 *
GENDER(MAN)	12(50.0)	14(56.0)	0.67***
SKIN TYPE			
TYPE 3	8(33.3)	10(40.0)	
TYPE 4	15(62.5)	13(52.0)	0.74***
TYPE 5	1(4.2)	2(8.0)	

Descriptive Statistics were reported as Med (IQR) and N (%).

*P-value of Mann-Whitney Test, **P-value of Fisher Exact Test, *** P-value of χ^2 -Test

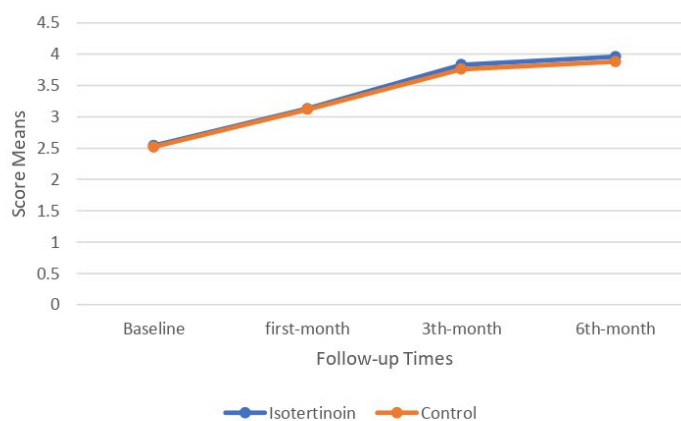


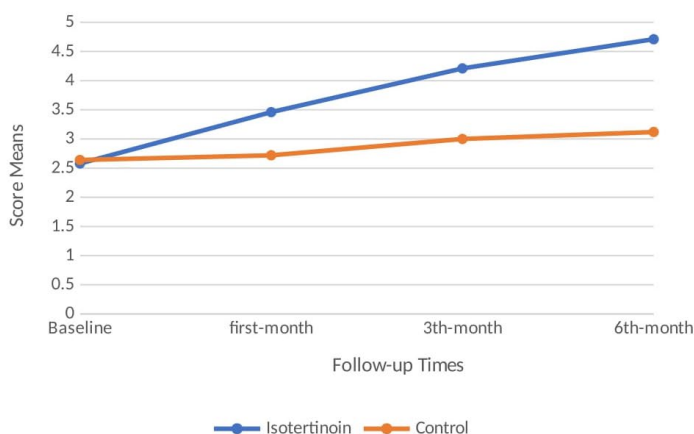
Figure 2: Comparisons of the differences in the surgeon’s score in study groups

Table 2: Comparisons of the differences in the surgeon's score

Surgeon's score	Tretinoin N=24	Control N=25	P value*
At the beginning	2.5(2.0-3.0)	3.0(2.0-3.0)	0.99
First month	3.0(3.0-3.0)	3.0(3.0-3.0)	0.94
Third month	4.0(4.0-4.0)	3.5(4.0-4.0)	0.61
Sixth month	4(4.0-4.0)	4.0(4.0-4.0)	0.44
P-value of trend**	<0.001	<0.001	

Descriptive Statistics are reported as Med (IQR)

* Mann-Whitney Test, **Friedman Test

**Figure 3:** The comparisons of the changes in the dermatologist score in study groups**Table 3:** Comparisons of the changes in the dermatologist score

Dermatologist score	Tretinoin N=24	Control N=25	P value*
At the beginning	3.0(2.0-3.0)	3.0(2.0-3.0)	0.69
First month	3.5(3.0-4.0)	3.0(2.0-3.0)	<0.001
Third month	4.0(4.0-4.7)	3.0(3.0-3.0)	<0.001
Sixth month	5.0(4.0-5.0)	3.0(3.0-3.0)	<0.001
P-value of trend**	<0.001	<0.001	

Descriptive Statistics are reported as Med (IQR)

* Mann-Whitney Test, **Friedman Test

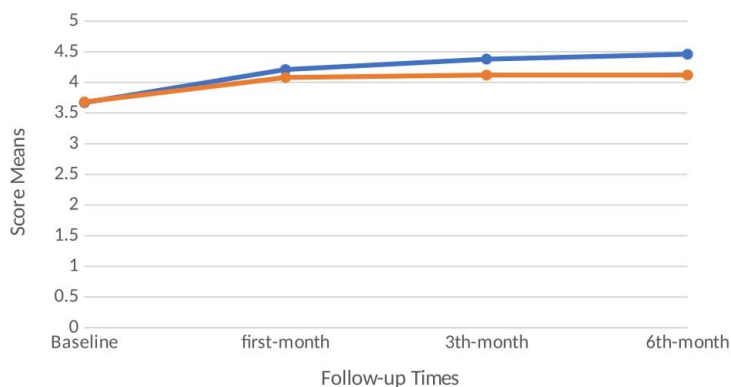
**Figure 4:** Comparisons of the changes in the patient scores in study groups

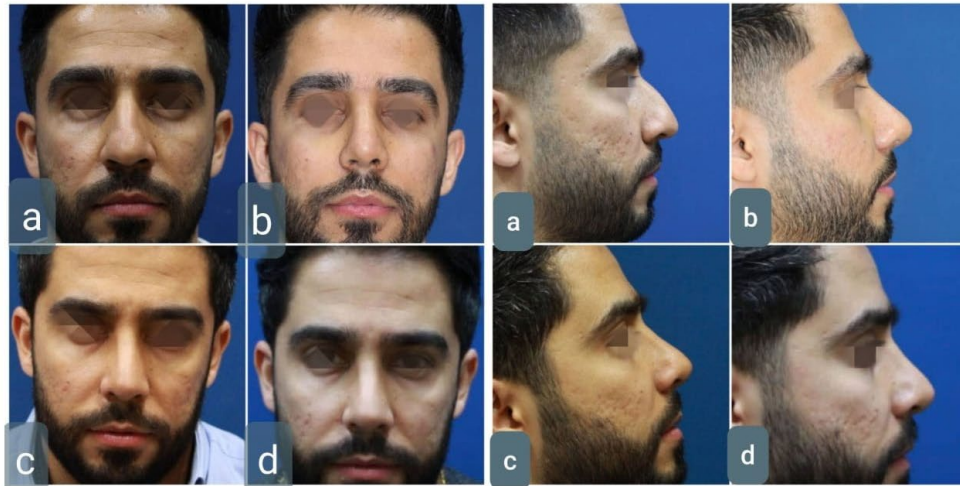

Figure 5: 3 Preoperative and postoperative photos of a thick skin patient who underwent rhinoplasty. A: preoperative photographs, B: 1 month after surgery, C: 3 months after surgery d :6 moth after surgery

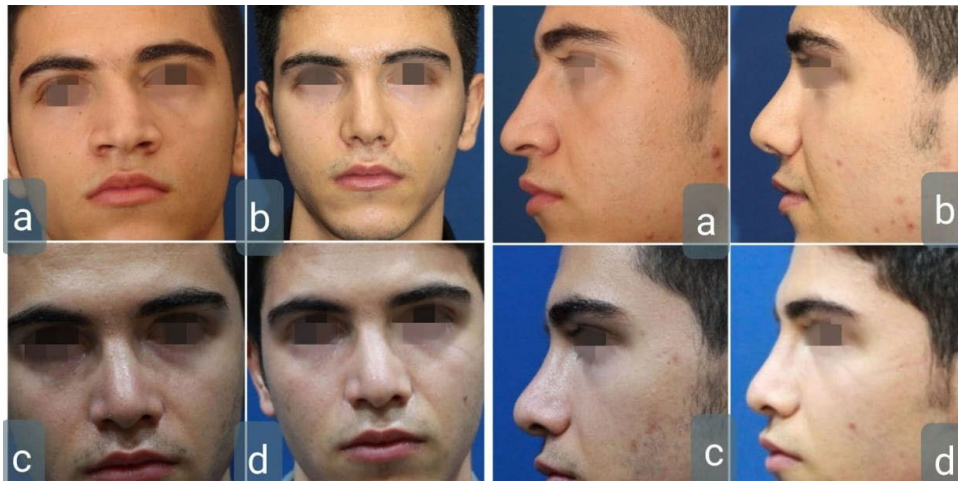


Figure 6: Preoperative and postoperative photos of a thick skin patient who underwent rhinoplasty with topical tretinoin use. A: preoperative photographs, B: 1 month after surgery, C: 3 months after surgery d :6 moth after surgery

DISCUSSION

The current study represents the first placebo-controlled clinical trial examining the use of topical tretinoin in rhinoplasty patients. While there was no significant improvement in cosmetic surgery outcomes as assessed by the otolaryngologist, patients who used topical tretinoin reported significantly greater satisfaction. They were rated higher by dermatologists than those in the control group. Additionally, we observed that the use of postoperative topical tretinoin improved patient skin health and satisfaction for at least 6 months after surgery. However, it did not have a significant

impact on the final surgical results (Figs. 5 and 6). Ultimately, creating a robust cartilaginous framework using appropriate surgical techniques and grafts is likely the most important factor in achieving optimal surgical outcomes. Nevertheless, improving patient satisfaction can enhance the effectiveness of communication between the surgeon and patient, reduce patient anxiety, and facilitate a quicker return to normal activities. The thickness of a patient’s skin can have a significant impact on the outcome of rhinoplasty. Patients with thin skin may experience quicker adaptation to newly generated skeletal structures and highlight more detailed features of the underlying skeleton. In contrast, thick-skinned patients may require

a longer adaptation period, and their skin may mask sharp lines and tip definition. Additionally, thick-skinned patients tend to experience more postoperative edema, which can prolong the healing process. Because of these factors, many individuals avoid aesthetic nose surgery due to concerns about achieving satisfactory results⁵.

Isotretinoin is one of the most effective drugs for managing severe acne, whether administered orally or topically⁶. Its mechanism of action involves reducing sebum secretion and the colonization of *Propionibacterium acnes*⁷. Additionally, Dispenza et al. proposed that isotretinoin might have an anti-inflammatory effect by decreasing the inflammatory response to bacteria⁸. Tretinoin is also employed in rhinoplasty procedures for patients with thick skin. Cobo and Vitery reported a noticeable improvement in texture and appearance of the facial and nasal skin, as well as better definition of the nasal tip, in all patients who were prescribed oral isotretinoin, as evidenced by pre- and postoperative photographs⁹. Sazgar et al. obtained similar results; however, they found no difference in tip definition between the two groups after 12 months⁴. It is worth noting that our study utilized topical tretinoin rather than systemic administration, and although we found that cosmetic surgery outcomes as assessed by the otolaryngologist did not differ significantly between patients using topical tretinoin and those in the control group, it is possible that systemic administration could produce different results.

It is recommended to discontinue oral isotretinoin use for 6-12 months prior to elective nasal surgery in order to prevent potential complications such as delayed wound healing or the formation of hypertrophic scars or excess granulation tissue¹⁰. A retrospective review involving three patients who had undergone systemic isotretinoin treatment reported experiencing tip deformities after rhinoplasty¹¹, but there have been no reports of complications associated with topical tretinoin use in rhinoplasty procedures thus far.

Studies have demonstrated that acne incidence increases by over 27% within the initial month following rhinoplasty surgery, compared to patients who underwent only intranasal surgery⁵. Long-term taping of the nose can also contribute to acne flare-ups. Isotretinoin use could lead to reduced acne formation and increased satisfaction with surgical results in a study involving 303 patients¹². In our

present study, based on assessments performed 3 and 6 months after surgery, patients who used topical tretinoin reported greater satisfaction, which may be attributed to the drug's skin oil-reducing and anti-acne effects. However, it is crucial to weigh the benefits against the potential drawbacks, particularly the side effects of topical tretinoin. Common side effects of topical tretinoin include burning, scaling, itching, or redness of the skin, darkening of the skin, lightening of normal skin color, and unusual dryness of the skin¹³.

It is important to note that the present study was conducted solely on primary rhinoplasty patients who underwent limited incisions of facial skin. Further extensive studies are necessary to determine whether these findings can be extrapolated to all types of skin surgeries. Oral isotretinoin use in rhinoplasty patients significantly decreases dermis and subcutaneous tissue thickness, as measured by ultrasonography¹⁴. In our study, a skilled dermatologist assessed patients to identify those with thick-skinned noses. However, it is critical to determine nose envelope thickness more precisely before surgery through medical radiologic imaging.

CONCLUSION

At a 6-month follow-up, the use of topical tretinoin after rhinoplasty did not significantly affect the final cosmetic results in patients with thick nasal skin.

ACKNOWLEDGMENTS

We would like to thank all the study participants, as well as staff of Clinical Research Development Unit, Imam Reza Hospital, Mashhad University of Medical Sciences, for their kindly cooperation. This work was supported by Research Project No 980390 as ENT residency dissertation.

CONFLICT OF INTEREST

The authors declare that there is no conflict of interests.

REFERENCES

1. Peck GC. Rhinoplasty: external shaving is invaluable in treating thick, sebaceous skin. *Aesthet Surg J* 1997;17(6):414.
2. Thomas M, D'Silva J. Ethnic rhinoplasty. *Oral*

- Maxillofac Surg Clin North Am* 2012;**24**(1):131–148.
3. Toriumi DM. New concepts in nasal tip contouring. *Arch Facial Plast Surg* 2006;**8**(3):156–185.
 4. Sazgar AA, Majlesi A, Shooshtari S, Sadeghi M, Sazgar AK, Amali A. Oral Isotretinoin in the Treatment of Postoperative Edema in Thick-Skinned Rhinoplasty: A Randomized Placebo-Controlled Clinical Trial. *Aesthetic Plastic Surgery*. 2018 Oct 4;**43**(1):189–95.
 5. Guyuron B, Lee M. An Effective Algorithm for Management of Noses with Thick Skin. *Aesthetic Plastic Surgery* 2017;**41**(2):381-387.
 6. Beckenbach L, Baron JM, Merk HF, Löffler H, Amann PM (2015) Retinoid treatment of skin diseases. *Eur J Dermatol* **25**:384–391
 7. Fox LP, Merk HF, Bickers DR (2006) Dermatopharmakologie. In: Brunton LL, Lazo JS, Parker KL (eds) *Goodman & Gilman's—Pharmakologische Grundlagen der Arzneimitteltherapie*. ABW Wissenschaftsverlag GmbH, Berlin, pp 1–73.
 8. Dispenza MC, Wolpert EB, Gilliland KL, Dai JP, Cong Z, Nelson AM, et al. Systemic isotretinoin therapy normalizes exaggerated TLR-2-mediated innate immune responses in acne patients. *J Invest Dermatol* 2012;**132**(9):2198–205.
 9. Cobo R, Vitery L. Isotretinoin use in thick-skinned rhinoplasty patients. *Facial Plast Surg* 2016;**32**(6):656–61.
 10. Ungarelli LF, Hetem CMC, Farina Junior JA. Is it safe to operate on patients taking isotretinoin? *Aesthetic Plast Surg* 2016;**40**(1):139–48.
 11. Allen B, Rhee J. Complications Associated With Isotretinoin Use after Rhinoplasty. *Aesthetic Plastic Surgery* 2005;**29**(2):102-106.
 12. Yahyavi S, Jahandideh H, Izadi M, Paknejad H, Kordbache N, Taherzade S. Analysis of the effects of isotretinoin on rhinoplasty patients. *Aesthet Surg J* 2020;**40**(12):NP657–65.
 13. McLane J. Analysis of common side effects of isotretinoin. *J Am Acad Dermatol* 2001;**45**(5):S188-94.
 14. Yigit E, Rakici IT, Seden N, Manav V, Kaygisiz I, Yigit O. The impact of isotretinoin therapy on the nasal skin thickness and elasticity: An ultrasonography and elastography based assessment in relation to dose and duration of therapy. *Aesthetic Plast Surg* 2022;**46**(4):1760–70.